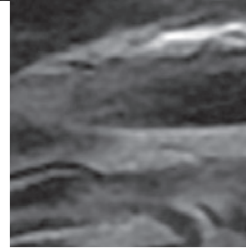
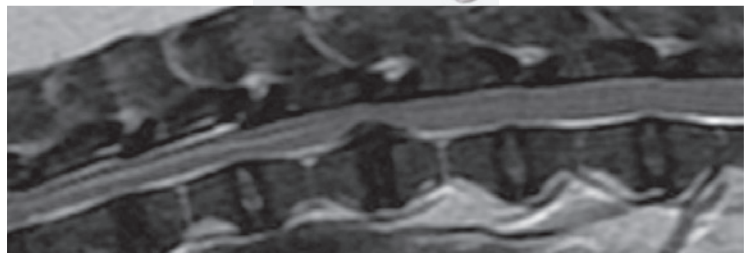

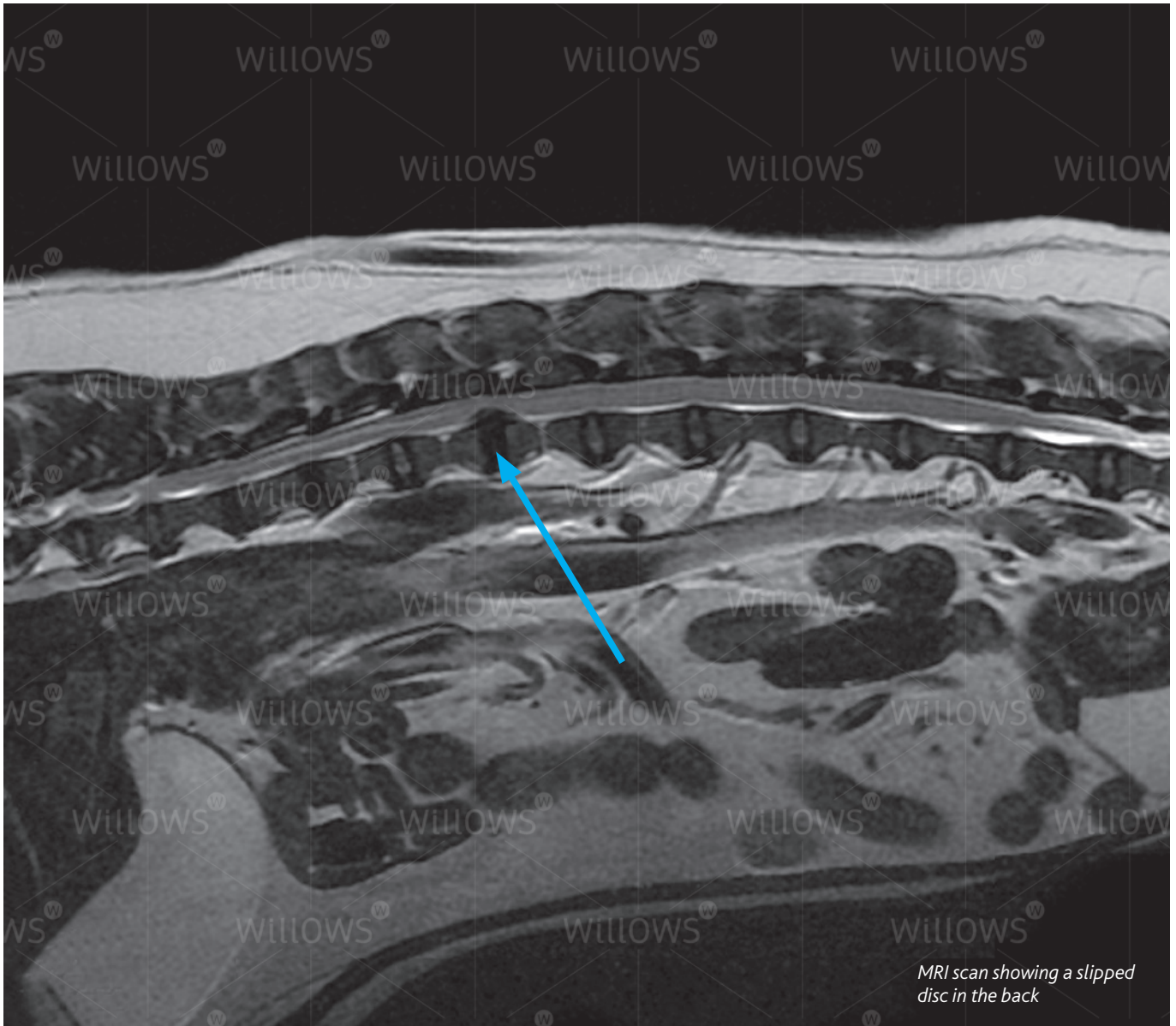


Specialist Referral Service  
Willows Information Sheets

# Thoracolumbar disc disease





*MRI scan showing a slipped disc in the back*

## Thoracolumbar disc disease

### What is meant by thoracolumbar disc disease?

A more common term for thoracolumbar disc disease is a 'slipped disc' in the back. The discs are the structures between the bones of the spine vertebrae that act as shock absorbers. They consist of a soft centre (the nucleus pulposus) inside a fibrous ring (the annulus fibrosus).

As in people, discs in dogs degenerate as they get older. This process results in the discs becoming dehydrated and losing their cushioning effect. They may then 'slip' in one of two ways. Firstly, the material in the centre of the disc can come out of the fibrous ring and injure the spinal cord (this is called a disc extrusion). Secondly, the fibrous ring may thicken and compress the spinal cord (this is called a disc protrusion). Either type of 'slipped disc' may cause back pain and nerve injury.

## Could my dog have thoracolumbar disc disease?

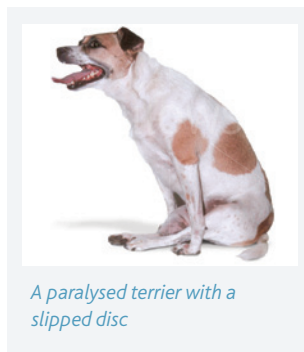
Any dog can develop a 'slipped disc' in their back, although the condition is very uncommon in dogs less than two years of age. Certain breeds, especially the ones with short limbs such as Dachshunds and Pekingese, are particularly affected. The German Shepherd dog is the most commonly affected large breed dog.

Signs may develop gradually or extremely quickly. Dogs can go from normal to being unable to walk within a few minutes.

Signs of thoracolumbar disc disease are either due to **(1) back pain** or **(2) nerve injury**.

### 1 Back pain

Signs of back pain may be obvious e.g. yelping and crying or arching of the back. More subtle signs include a reluctance to jump or climb and a tense abdomen (tummy).



*A paralysed terrier with a slipped disc*

### 2 Nerve injury

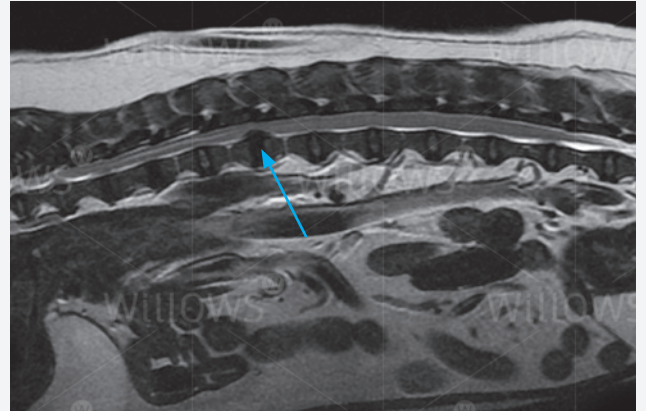
Discs that 'slip' in the thoracolumbar region of the spine (the back) may compress the spinal cord and cause varying degrees of nerve injury. This may range from mild weakness or inco-ordination of the back legs (hind limbs) through to paralysis and incontinence. In severe cases the ability to feel pain in the hind limbs and tail is lost.

## How is thoracolumbar disc disease diagnosed?

A neurological examination is necessary to assess the severity of any spinal cord injury. This involves testing numerous reflexes such as the knee-jerk (patellar) reflex. Checking the dog's ability to feel pain in the hind limbs and tail is also important. The examination often helps the specialist to localise which area of the spine is affected.

There are many other causes of back pain and nerve injury in addition to thoracolumbar disc disease. As a result investigations are necessary to confirm a 'slipped disc' and exclude these other conditions.

Normal X-rays (radiographs) of the back may reveal evidence of thoracolumbar disc disease, such as a narrowed disc space or a calcified disc. However, more advanced investigations are necessary to see which disc has actually slipped and assess the severity of any spinal cord compression. Of these advanced imaging techniques, an [MRI scan](#) provides the best method of investigating this condition. Instead of X-rays, MRI uses high powered magnets and a computer to generate images of the spine. MRI provides information not only on the health and position of the discs in the back but also on the nature



*MRI scan showing a slipped disc in the back*

of any injury to the spinal cord. This makes diagnosis more accurate and assists greatly in deciding the best course of treatment for the individual patient.

Myelography is another imaging technique which can be used for investigating thoracolumbar disc disease. This involves injecting a dye (contrast agent) around the spinal cord and obtaining multiple X-rays to assess the flow of the dye to see if it is interrupted at the site of the slipped disc. Injecting around the spinal cord is not without risk of causing further damage to already compromised nerve tissue. MRI is less invasive than myelography with less risk of side-effects, and for most patients MRI provides the best option for investigation. Both MRI and myelography require the dog to have a general anaesthetic.

Occasionally it is necessary to collect some fluid (cerebrospinal fluid – CSF) from the spine and send it to a laboratory for analysis. This test assists in the diagnosis of inflammatory conditions that affect the spine.

## How can thoracolumbar disc disease be treated?

Thoracolumbar disc disease can cause severe spinal injury. Signs can develop extremely rapidly (acute spinal cord injury) and the damage can be irreversible. This is in contrast to people where back pain is the key feature and spinal cord injury is uncommon. Since thoracolumbar disc disease can be a life-threatening condition, some dogs need to be treated as an emergency.

The two principle methods of managing thoracolumbar disc disease are **(1) conservative treatment** and **(2) surgery**.

### 1 Conservative treatment

When dogs with thoracolumbar disc disease are managed conservatively their exercise must be restricted. Short lead walks for toileting purposes may be necessary, with strict confinement at other times. The hope is that the 'slipped disc'

will heal, any back pain subside and the spinal cord recover from any injury. Painkillers may be necessary and possibly other drugs, such as muscle relaxants. It is important to ensure that affected dogs continue to urinate. Failure to do so may result in distension of the bladder and infection (cystitis). Manual expression or catheterisation of the bladder may be required.

## 2 Surgery

The aims of surgery are to remove any disc material that is compressing the spinal cord and to prevent any more disc material 'slipping'. Decompressive surgery involves removing a section of bone from around the spine (laminectomy) to enable retrieval of disc material. Further 'slipping' can be prevented by cutting a small window in the side of the disc and removing material in the centre (disc fenestration). Occasionally vertebral stabilisation (fusion) procedures are necessary, especially in large dogs.

## What is the outlook with thoracolumbar disc disease?

The outlook or prognosis depends on a number of factors including the severity of spinal injury, the duration of spinal injury and how the condition is treated.

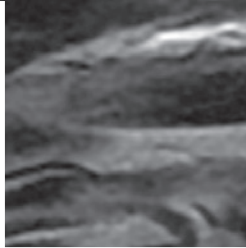
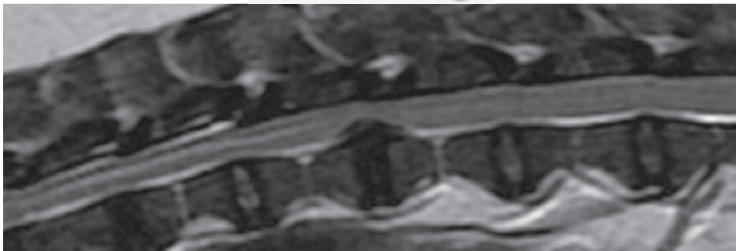
Conservative management can be successful in cases with back pain and in those with mild spinal cord injury. Unfortunately some dogs continue to deteriorate with this approach or recover only to have a recurrence weeks or months later.

The success rate with surgery is generally high, provided the dog still has pain perception in the hind limbs and the spinal cord hasn't been compressed for a long time (chronic spinal cord injury).

Nursing care is an important aspect of both conservative and surgical management of thoracolumbar disc disease. Dogs that are unable to use their hind limbs will need assistance to go outside. Incontinent dogs require their bladders to be emptied regularly. Physiotherapy exercises can be useful in many patients and hydrotherapy is sometimes indicated.

***If you have any queries or concerns, please do not hesitate to [contact us](#).***

Specialist Referral Service  
[www.willows.uk.net](http://www.willows.uk.net)



The information contained is proprietary to Willows Veterinary Centre & Referral Service and may not be modified, reproduced, distributed or utilised in any manner in whole or in part, without the express prior written permission of Willows Veterinary Centre & Referral Service.