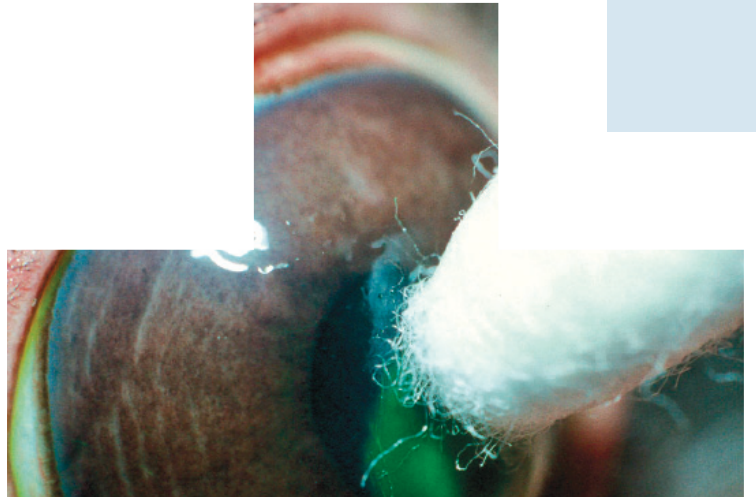
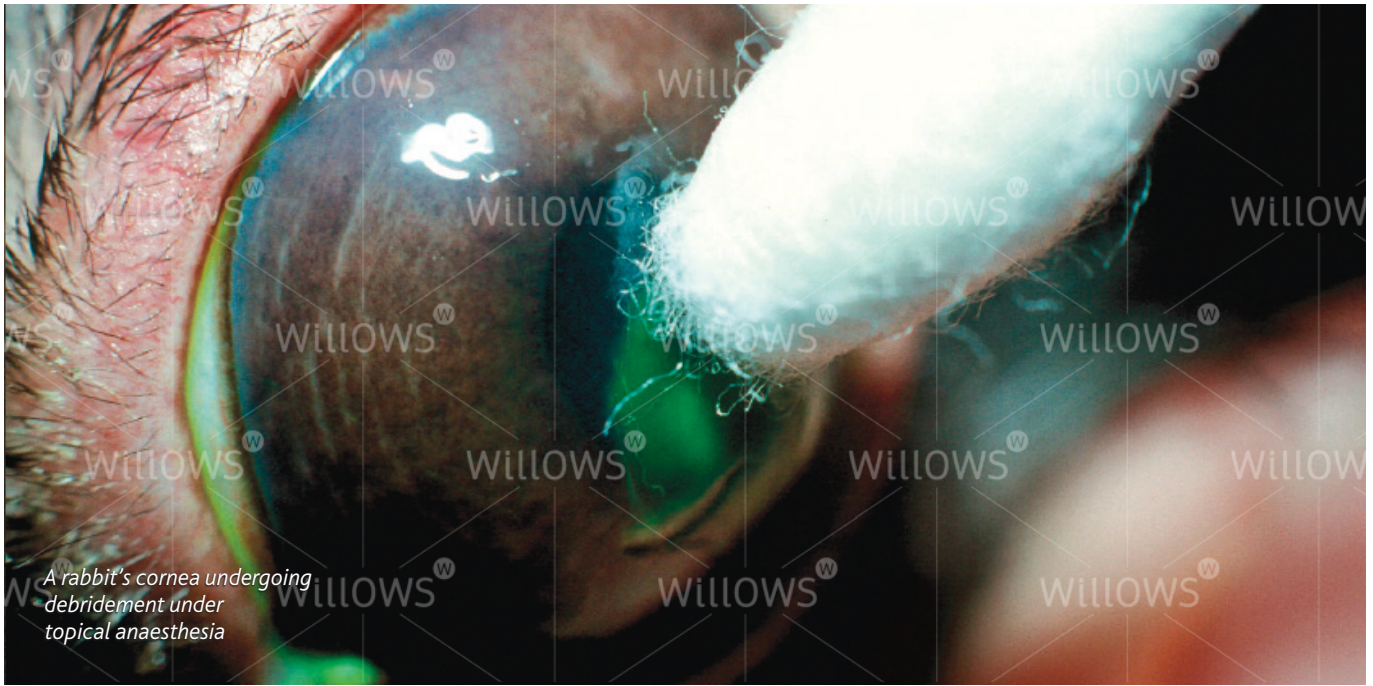


Specialist Referral Service
Willows Information Sheets

Recurrent corneal erosions (indolent ulcers)





A rabbit's cornea undergoing debridement under topical anaesthesia

Recurrent corneal erosions (indolent ulcers)

What is the cornea?

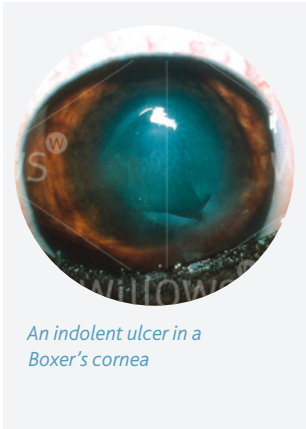
The cornea is the clear window of the eye. It is a delicate structure which is less than a millimetre thick. In order to be transparent, the cornea has no blood vessels. It consists of three layers which are arranged like those of a sandwich. The three layers comprise: 1) the epithelium – this is the thin outer 'skin' of the cornea 2) the stroma which is the much thicker middle layer of the 'sandwich' 3) the endothelium – this is the inner layer of the cornea and is very thin indeed (only one cell thick).

What is a corneal ulcer?

Any injury involving the cornea can be described as an ulcer. Generally, corneal ulcers are described as superficial or deep depending on whether they just involve the outer skin (the epithelium) – in which case they are called superficial ulcers or erosions, or whether they extend into the middle layer (the stroma) – in which case they are called deep ulcers. Most superficial ulcers heal rapidly as the cells of the surrounding outer 'skin' (the epithelium) slide and grow into the defect. The new skin that grows then sticks to the tissue underneath. Most superficial ulcers will have healed within a week.

How do I notice that my dog has an ulcer?

The cornea is sensitive because it has a lot of nerve endings, and ulceration is usually associated with quite marked discomfort because the nerves are exposed. Signs of eye discomfort include weeping, blinking, squinting, pawing at the eye and general depression.



An indolent ulcer in a Boxer's cornea



The same ulcer as shown previously, now stained with a dye to show up the defect

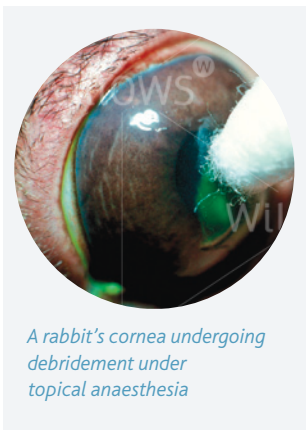What makes an ulcer indolent?

An indolent ulcer is an ulcer which fails to heal in the expected time. It then tends to cause ongoing discomfort and irritation.

Eyes affected with indolent ulcers try to grow a new surface skin over the defect, but the incoming cells fail to stick down onto the layer underneath (the stroma). As a result, a thin layer of loose tissue can often be seen surrounding the ulcerated area. The reason why the cells fail to stick is not fully understood but is believed to be mainly because the epithelial cells fail to form tiny 'feet' that normally hold on to the tissue underneath.

Are certain breeds predisposed to develop indolent ulcers?

Certain breeds are predisposed to develop indolent ulcers – Boxers, Corgis, Staffordshire Bull Terriers and West Highland White Terriers are often affected. However, any dog can develop an indolent ulcer, and older patients are more commonly affected. Once a dog has suffered an indolent ulcer in one eye, it may develop one in the other eye or recurrence of ulceration in the first eye. This can happen at any time after the first ulcer (sometimes years later).



A rabbit's cornea undergoing debridement under topical anaesthesia

What treatment options are available if my dog has an indolent ulcer?

It is not possible to achieve healing of indolent ulcers with the use of antibiotic or false tear ointments alone. In order for healing to occur, it is important that all loose tissue is removed and that the exposed stroma is treated and 'freshened up' to allow adhesion of new epithelial ('skin') cells. The process of removal

of loose epithelium is called 'debridement' and in most patients it can be carried out on the consulting room table with the use of local anaesthetic drops in the eye. Following the debridement, the exposed stroma is usually cauterised with phenol and/or small dot-like scratches are made with a fine needle to allow the 'feet' of the new cells to take hold. The latter procedure is called a 'punctate keratotomy'.

In very fractious patients, it may be necessary to give a sedative to perform these procedures.

More severe and longstanding cases require more radical treatment under a general anaesthetic. In this instance all diseased epithelium and some of the underlying stroma is removed. This procedure is carried out under the operating microscope with a sharp knife. The operation has a high success rate but is not suitable for every case.

What care will be required following debridement and cautery?

Usually, a broad spectrum antibiotic will be dispensed to be applied three times daily to help to prevent infection. In some cases, it may be necessary to give a drug (atropine) which widens the pupil and reduces pain associated with the ulcer. Often patients with an indolent ulcer will receive a painkiller which is given with food.

In some patients, the pain associated with the ulcer appears more severe than in others. Often in such cases, a bandage contact lens can be placed in the eye. Such a lens is not likely to significantly affect the healing time but will cover exposed nerve endings and provide pain relief. Unfortunately, it is not possible to fit contact lenses as effectively for dogs as can be done for humans, and sometimes the lens is lost soon after application.

How does the eye appear during healing of the ulcer?

In some patients, healing of the ulcer occurs fast and the cornea will only be slightly cloudy during treatment. However, in patients where healing of the ulcer is slow, it is common to find that blood vessels grow into the cornea and that pink granulation tissue forms to cover the defect. During this time, the eye may appear very red and odd looking. However, once the defect is fully covered, the granulation tissue will gradually clear over a period of months, leaving only minor corneal scarring in the majority of cases. Vision in most patients will return to normal or near normal after an episode of indolent ulceration.

How long does an indolent ulcer take to heal on average?

With a single treatment of debridement and cautery, approximately 80% of indolent ulcers heal within one to two weeks. The remaining

20% may require more than one treatment and on occasions, it can take several weeks until full healing of an indolent ulcer is achieved.

The option of surgery for an indolent ulcer may have to be reconsidered if it fails to heal after several attempts at debridement and cauterisation and/or punctate keratotomy.

What complications can occur if my pet has an indolent ulcer?

The biggest concern is certainly the possibility of infection. This can occur even if a suitable broad spectrum antibiotic is used on a preventative basis. If infection occurs, indolent ulcers may become deep and may require urgent surgical intervention.

Can my own veterinary surgeon carry out debridement, cauterisation and punctate keratotomy?

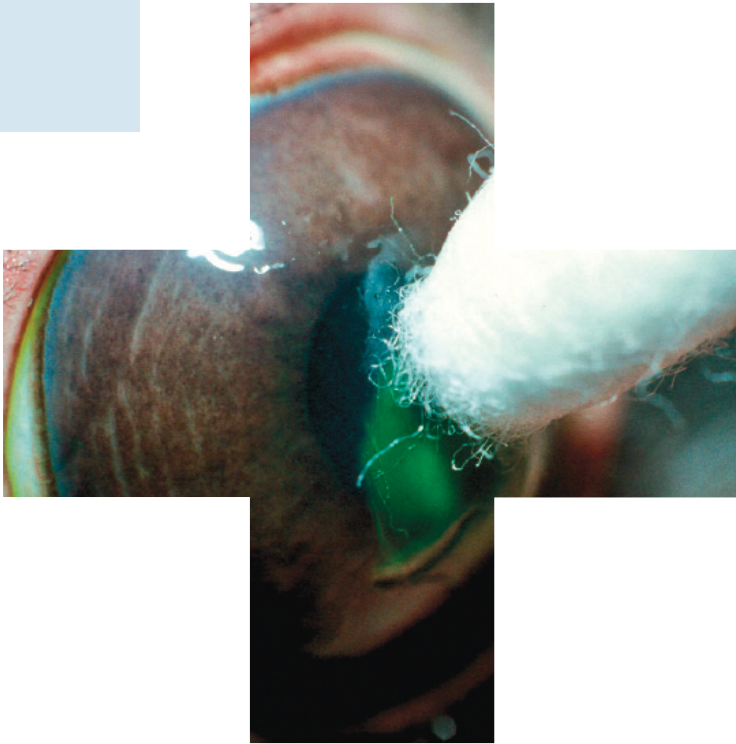
If you have been referred for the treatment of the indolent ulcer, it is likely that your veterinary surgeon would prefer a veterinary eye specialist to carry out the treatment.

Do I have to return to the eye specialist for the aftercare?

Until healing of the indolent ulcer is achieved, it is usually advisable that the patient returns to the specialist to ensure satisfactory progress. On occasions, treatment will be shared between your veterinary surgeon and the eye specialist in order to reduce the travelling involved for you. Once the ulcer has fully healed, patients should not require frequent veterinary attention and a return to the eye specialist will only be necessary in selected cases or if the problem recurs in either eye.

If you have any queries or concerns, please do not hesitate to [contact us](#).

Specialist Referral Service
www.willows.uk.net



The information contained is proprietary to Willows Veterinary Centre & Referral Service and may not be modified, reproduced, distributed or utilised in any manner in whole or in part, without the express prior written permission of Willows Veterinary Centre & Referral Service.